

Chris Bradfield, 262-2024  
213 McArdle , [Bradfield@oncology.wisc.edu](mailto:Bradfield@oncology.wisc.edu)

**Assignments:** Each lecture summary sheet will have questions within the text that are **bold and in italics**. Please be prepared to answer these questions in class. In addition written short answers to these same questions will be due four times throughout the next few weeks. I will assign the exact dates in class depending on how fast we move through the material.

**Assigned Reading for unit I:** These readings are meant to provide background.

- 1) Briefly review liver physiology before the first session (any physiology text will do).
- 2) Venook, AP (1994). Hepatocellular carcinoma: Too many options? J. Clin. Oncology. 12:1323.

## UNIT I: Liver Biology, Pathology and Cancer

It is important to understand liver biology, pathology and cancer because:

- 1) The liver is one of the most common sites of human malignancies (worldwide).
- 2) Hepatocellular carcinoma has an extremely low overall survival rate.

### Review of Basic Liver Biology

Before we can talk about these issues, we must first review liver physiology. The liver plays a primary role in homeostasis. It regulates levels of circulating nutrients (e.g., amino acids, glucose), excretes waste products into the bile (e.g. bilirubin, toxicants), reduces circulating ammonia through production of urea, produces a battery of important serum proteins (e.g., albumin, clotting factors), produces bile acids required in digestion of lipids and acts the primary site of a metabolic defense against carcinogens that enter through the GI tract.

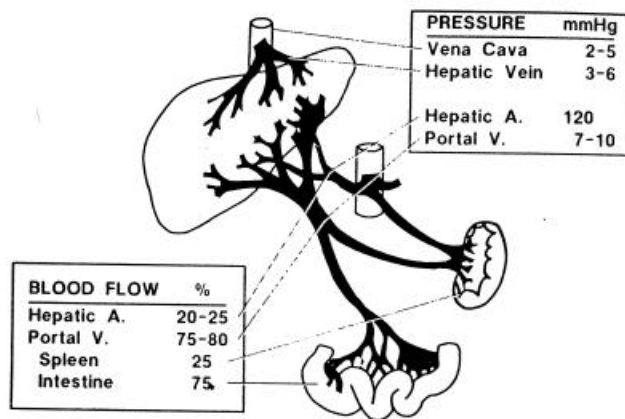


Figure 1. Blood supply of the liver.

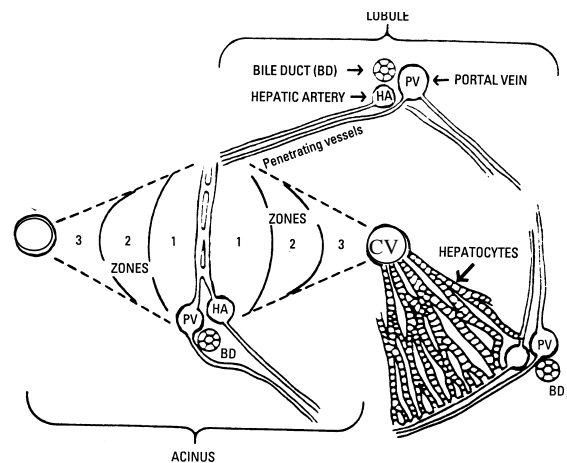


Figure 13-1. Schematic of liver operational units: the classic lobule and the acinus.

**Two views of liver physiology. Left:** The liver is perfused by venous blood that has already perfused the GI tract. This blood is rich in nutrients and toxicants from food and bacterial GI flora. The venous flow through the liver is called the "Portal Circulation" because it represents a port between the capillary bed of the GI tract and the capillary bed of the liver. The liver also receives venous blood from the spleen (Taken from "Hepatotoxicology," Meeks, Harrison and Bell, eds., CRC Press, Boca Raton FL, 1991). **Right:** A schematic of the liver lobule (not to be confused with liver lobe). Both venous and arterial blood mixes in the sinusoids and flows towards the central vein. Thus, cells are bathed in both venous and arterial blood. Bile flow is in the opposite direction toward bile duct and is separate from blood. Bile forms in a common duct, is stored in the gall bladder and enters into the intestine. Some pathologists prefer to think of the functional unit of the liver as the acinus. This is the oval region between two hepatic veins and can be described by zones of perfusion.

**Liver Cell types.** Hepatocytes (70-90% of liver mass, depending on the species) metabolize and excrete into sinusoids or bile canaliculi. Many hepatocytes are not terminally differentiated and can divide to produce more

hepatocytes. Kupffer cells (macrophages) phagocytize particulates and cell debris. Each sinusoid is lined with endothelial cells which are highly fenestrated to maximize absorption. The “portal triad” is the portal vein, the hepatic artery and the bile duct (three components=triad). The bile duct is lined by epithelial cells. Oval cells are rare cells that reside primarily near the portal triad. They are believed by some to be liver stem cells. This picture shows two ways of viewing the liver 1) as a lobule, a central vein surrounded by portal triads (right) or 2) an acinus the circulatory system between two central veins (CV). ***In terms of carcinogenesis, does it matter which cells of the liver are the stem cells?***

**Regenerative Capacity of the Liver.** Under normal physiological conditions, liver size is tightly controlled in almost all species. When baboon livers are transplanted into humans, they grow to the mass of a human liver. The liver has a remarkable capacity to regenerate after cellular damage or tissue removal. Regeneration is mostly the result of increased mitosis of hepatocytes. Removal of as much as 80-90% of the liver can be restored in the absence of disease. Livers from rats have been subjected to partial hepatectomy (removal of 2/3 of the liver) 12 times in a row. Each time, the liver is restored to its normal size within a few weeks. It has been estimated that one rat hepatocyte has the capacity to generate at least 50 livers (Science. 276:60).

**Changes in liver size, function and structure.** Although normal liver size is tightly controlled, certain stress conditions can increase liver size markedly. This increase in liver size is primarily through cell division (hyperplasia), but may in part be due to increases in cell size (hypertrophy). **Examples: 1) Regenerative response to chemical toxicity:** A variety of chemicals can cause liver cell death. Chronic alcohol consumption can cause liver necrosis and degeneration. Other common liver toxicants are drugs like acetaminophen and tetracycline. When hepatocellular toxicity occurs, the liver regenerates to replace lost cells and lost function. In many cases, the cell death is accompanied by an inflammatory response. The continual regeneration (cell loss and replacement by growth and proliferation cycles) leads to loss of cellular organization and increased collagen synthesis and deposition as part of the remodeling process. The increase in collagen fiber deposition is called *fibrosis*. *Cirrhosis* is a disease state that results from unchecked hepatocellular damage and fibrosis. It is marked by extensive scarring and nodularity of liver parenchyma, as well as a related decrease in liver function. Liver cirrhosis is one of the top ten causes of death in the US. Fibrosis and cirrhosis can lead to decreased efficiency of circulatory flow and thus decreased capacity of the liver to maintain homeostasis. **2) Proliferative and adaptive response to chemical exposure:** In response to many drugs, pollutants and industrial chemicals, the liver will undergo an adaptive hyperplasia and hypertrophy. In response to high levels of barbiturates, DDT, phthalate esters, dioxins etc the liver can increase from 2-3 times its normal size. In most cases, this increase in size is not accompanied by fibrosis or significant remodeling. At the cellular level, hepatocytes under these conditions have marked increases of smooth endoplasmic reticulum (ER). This ER is the site of most chemical oxidation reactions (to be discussed later). This response appears to be an adaptive change to help the liver handle the increased metabolic needs imposed by chemical exposure. **3) Inflammatory response to infection:** The liver is common site of attack for many blood borne infectious agents. Among them are a number of hepatotropic viruses (i.e., hepatitis virus). There are 5 known hepatitis viruses, that are genetically unrelated, known as A, B, C, D and E. The B and C strains induce a chronic inflammatory response in 5-50% of infected individuals (respectively).

**Residual Capacity of the Liver.** The liver has considerable residual activity, partial hepatectomy of 2/3 of the liver is well tolerated. Liver cirrhosis, due to alcoholism etc may destroy much of liver function without clinical detection. Liver failure does not usually occur until 80-90% of the liver parenchyma is destroyed. Removal of 1/3 of the liver can easily go undetected, biochemically. This is especially noteworthy since under such conditions, greater than 90% of the remaining hepatocytes can be already stressed by compensatory growth and cell division. Cell division starts and is greatest in the periportal area, over a period of 48 hours mitotically active area spreads to the pericentral areas (zone 1 to zone 3 in the acinus).

***What diagnostic parameters would be good indicators of liver failure or significant liver damage, why?***

**Ploidy:** Hepatocytes are unusual in that their ploidy can be quite high. For example the normal adult rat liver is comprised of mostly tetraploid cells (85-90%). One to 3% are octaploid and only about 10% are diploid. Of the tetraploid cells, 20% are binucleate. This increase in ploidy occurs through development and aging. For example, it is commonly thought that binucleate cells predominate at three weeks and mononuclear tetraploid cells appear later. In addition, no one has yet provided a clear map of where diploid and higher ploidy cells reside throughout development. It is thought by many that the diploid cells are periportal and ploidy increases toward the central vein. Humans tend to have lower levels of tetra and octaploid cells. Older mice may have a large number of 32N hepatocytes. ***What do you think the significance of this higher ploidy is? Which cells would you predict are the best candidates as liver stem cells, why?***

## LIVER CANCER

**Types of Liver tumors.** Liver tumors may be either primary (originated at the site) or secondary (from a metastases from another tissues, "mets"). The liver is a common site for mets from other organs. Liver tumors can be classified as either benign (mild, nonmalignant) or malignant ("tending towards death"). **Can you think of an organ that is most likely to yield mets to the liver, why? How could you predict where liver tumors would metastasize to?**

Common types of benign liver tumors, include hemangiomas (a swelling or cluster of blood vessel cells), focal nodular hyperplasia and adenomas (a cluster of hepatocytes, often encapsulated). Incidence of hepatocellular adenomas is much higher in men than women (pointing to a role for steroid hormones in tumor growth and progression, to be discussed later). In women, adenomas are associated with estrogen exposure as can be seen in high dose estrogen therapy (birth control). Paradoxically, in men, adenomas are often associated with use of anabolic steroids. Clinical evidence of benign tumors may never be observed. When they are observed clinically, it is usually due to presentation with right quadrant pain or symptoms related to pressing onto neighboring structures. Many benign tumors are discovered at autopsy and can be quite common. A large percentage of the general population will have liver tumors at their death. Many may not be observed due to their small size. The term benign can be misleading. First, the liver is highly vascularized and soft in structure. When the integrity of liver structure is compromised by a tumor (even a benign one), the surrounding tissue is prone to hemorrhage, which can lead to crisis or death. Second, cells within some benign tumors apparently can progress into malignant forms.

The most common types of diagnosed malignant liver tumors are hepatocellular carcinoma (HCC)=80-90%, these tumors arise from hepatocytes. A second common tumor in the liver is the cholangiocarcinoma (7-15%), these tumors arise from bile duct cells. Rare types of malignant liver tumors include, angiosarcomas (from blood vessel endothelial cell tumor) and lymphomas (from Kupffer cells). Malignant tumors are classified by four stages. Staging defines the treatment protocols and predicts survival:

Stage (simplified)	5 yr survival
I Tumor is smaller than 2 cm and has not invaded blood vessels	80%
II Tumor is smaller than 2cm but has invaded blood vessels (or is larger than 2m and has not invaded)	40%
III Cancer has spread to lymph nodes.	3%
IV Cancer has metastasized	1%

**If you can cut out a big piece of liver with a tumor and healthy liver will regenerate, why is the survival rate for HCC so low (5 year survival for all individuals diagnosed with hepatocellular carcinoma is 6% percent) ?**

**Incidence of HCC.** It is estimated that approximately 1.25 million people die from HCC each year.

REGION	INCIDENCE/100,000
North and South America, Britain, Australia	3
Mozambique and Thailand	100
Singapore	34
Zimbabwe	65
So Africa	28
US White Males	2.4
US Black Males	8
Males >Females	

Data taken from Cancer of the Hepatobiliary System in "Cancer, Principles & Practice of Oncology. 3rd Edition(DeVita et al Eds.) Lippincot Co (and references therein).

**What does this data suggest about mechanism. What experiments would help you distinguish between the possibilities?**

**Diagnosis.** Benign tumors are often diagnosed as incidental findings at autopsy, laparotomy or radiology (resulting from nonspecific complaints or unrelated procedures). These tumors are often clearly visualized by CT scan, ultrasound or MRI (expensive). A great deal of hepatocellular adenomas yield hemorrhages. Only a small

percent of detection is due to right quadrant pain. Malignant tumors often present as right quadrant pain, anorexia or nonspecific complaints like anorexia. About 1/3 of these patients are asymptomatic. CT scans with and without contrasting agents (angiography) are most common. Ultimately biopsies must be performed.

**Biopsies (minor surgical procedures to remove and analyze a small piece of the tumor) are contraindicated when the tumor is highly vascularized, why?. Why are gynecomastia (development of male mammary glands) or spider angiomas (“spider veins” similar to those seen in pregnancy) commonly seen in malignant liver cancer?**

The progression to cancer has been characterized as cellular dedifferentiation. That is, a cell becoming more embryonic, less differentiated. This is because most differentiated cells don't divide, but stem cells and embryonic precursors do. In liver cancer, this has been used to some (small) advantage in that certain markers of fetal liver, e.g.  $\alpha$ -fetoprotein (AFP) and  $\alpha$ -1 globulin have been used in diagnosis and prognosis. Although elevated AFP can also be indicative pregnancy and other tumor types (e.g., germ cell tumors), it is elevated in 70% of HCC. Patients with AFP levels higher than 10,000 ng/ml have half the survival rates as those with AFP below this level.

**Treatment.** “Surgery is the only curative modality for HCC”. If the cancer is localized, surgical removal (“resection”) can be performed (up to 80% removal has been done). When partial hepatectomy is possible, it has resulted in a 5-year survival of 10%-30. Resection is poorly tolerated in patients with cirrhosis or chronic active hepatitis since the residual capacity of the remaining diseased liver may be too low to support life (many HCC patients have these conditions). Transplantations are also contraindicated by cirrhosis, but may be a choice when mets have not appeared and liver function cannot be restored by resection. Although liver transplantation should be an effective therapy, donors are limited.

Standard chemotherapy approaches and external beam radiation as treatment modes for HCC have little utility. The liver is very sensitive to radiation toxicity, as is the surrounding viscera. Thus, the dose required to achieve a decrease in tumor size will kill the host due to liver failure etc. Similarly, chemotherapy as a primary or adjuvant approach has had no benefit. The reason for this is unclear, but the liver has an incredible capacity for metabolism and eliminate drugs (this will be discussed later). A good reason not to use chemotherapy is that these individuals often have marked decrease in their ability to metabolize drugs and thus often experience significant systemic toxicity.

Patients with unresectable disease have an average life expectancy of 6 months. These patients should always be considered for clinical trials in a research setting. Some promising approaches now under clinical evaluation are (as described at the NCI web site): 1. For selected patients with localized unresectable hepatomas, liver transplantation may offer a potentially curative treatment option. 2. Chemotherapy (regional infusion of the liver): Chemotherapeutic agents may be infused with a subcutaneous portal or implantable pump via a catheter placed in the hepatic artery. Older studies that use standard agents have demonstrated responses in 15%-30% of such cases, but newer agents and techniques (that is, biodegradable microspheres) have been evaluated in pilot trials. Many patients are not candidates for these approaches, which often require surgical intervention. 3. Cryosurgical destruction of HCC and intratumor injections of alcohol are newer modalities, particularly for patients with cirrhosis for whom resection is unsafe. 4. Radiolabeled polyclonal antiferritin antibody produces decreased tumor mass in some patients, yielding them resectable.

#### General Reading:

- 1) Michalopoulos, GK and DeFrances, MC (1997). Liver Regeneration. Science. 276:60.
- 2) Ponder, KP (1996). Analysis of liver development, regeneration and carcinogenesis by genetic marking studies. FASEB J. 10:673-682
- 3) Gumucio, JJ and Chianle, J (1988). Liver cell heterogeneity and liver function. In The Liver Biology and Pathobiology, 2nd Edition (Schacter and Shafritz eds.) Raven Press, NY.

#### Web Sites:

<http://vh.radiology.uiowa.edu/Providers/Textbooks/LiverPathology/Text/11Index.html> (slow but a great way to look at multiple types of liver tumors in color)

<http://www.graylab.ac.uk/cancernet/101195.html> (A nice way to review primary liver cancer, very clear with a lot of general information).

<http://www.medsch.wisc.edu/anatomy/histo/htm/tlivbase.htm> (Has some great shots of portal triads etc, nice histo site).